Caso 2: AM, 25 anos, fem, dor precordial típica

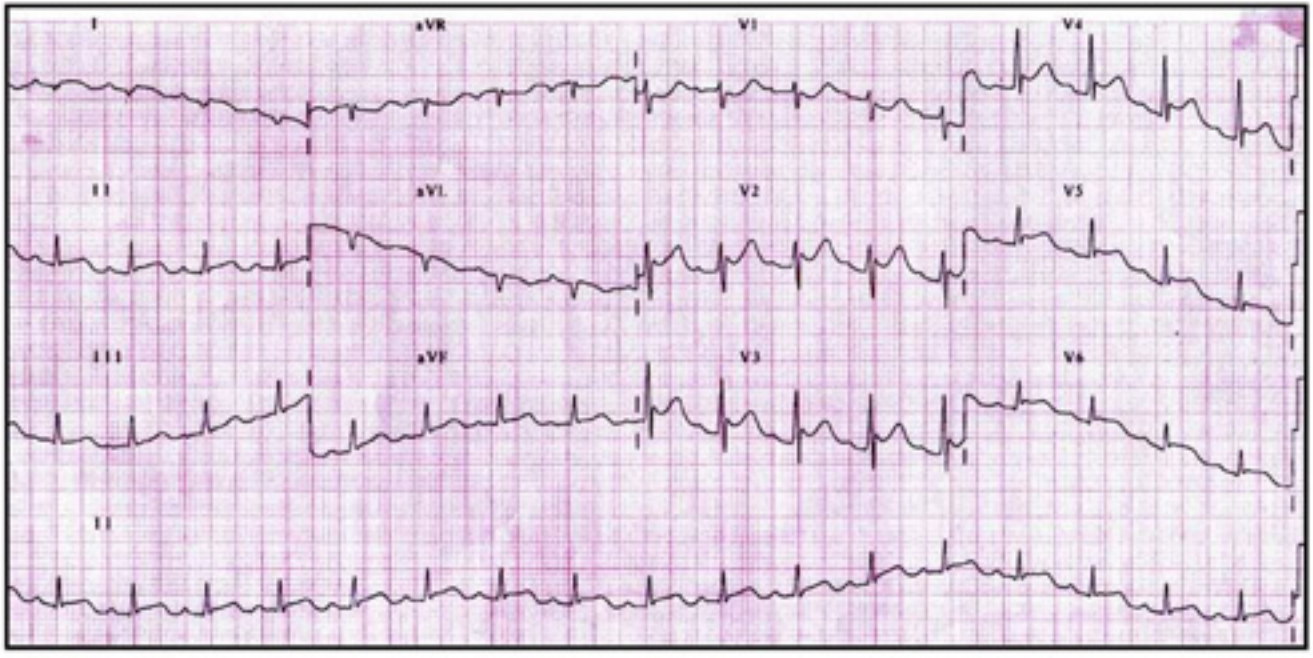

IAM ântero-lateral ?