

Eustachian Valve Endocarditis Associated with Complicated Cardiac Resynchronization Therapy Defibrillator Generator Pocket Infection

Endocardite da Válvula de Eustáquio Associada à Infecção Complicada do Gerador de Terapêutica de Ressincronização Cardíaca com Desfibrilador

Maria Inês Fiuza Branco Pires¹, Inês Almeida¹, Maria Luísa Gonçalves¹, João Miguel Santos¹, Miguel Correia¹

¹Cardiology Service, Tondela-Viseu Hospital Center, EPE, Viseu, Portugal.

A 76-year-old male with ischemic cardiopathy was admitted with fever and purulent drainage from cardiac resynchronization therapy defibrillator generator pocket, two months after its implantation. Prompt device removal was performed. Cultures identified methicillin-sensitive *Staphylococcus aureus*. Transthoracic echocardiography revealed a highly mobile filamentous right atrial mass with 30mm in length, apparently attached to interatrial septum (Figure 1 and Video 1). Transesophageal echocardiography (TEE) showed that the echogenic mass was attached to the Eustachian valve (EV) (Figure 2 and Video 2) and the diagnosis of EV endocarditis was made. There was no involvement of tricuspid valve. The patient completed a 4-week course of flucloxacillin, with good clinical response and without embolic

complications. Repeat TEE revealed a significant decrease in vegetation size (Figure 3 and Video 3).

Authors' contributions

Research conception and design: MIFB Pires, I Almeida, ML Gonçalves, JM Santos, M Correia; data collection: MIFB Pires, I Almeida, ML Gonçalves, JM Santos, M Correia; manuscript writing: MIFB Pires, I Almeida, ML Gonçalves, JM Santos, M Correia.

Conflict of interest

The authors have declared that they have no conflict of interest.

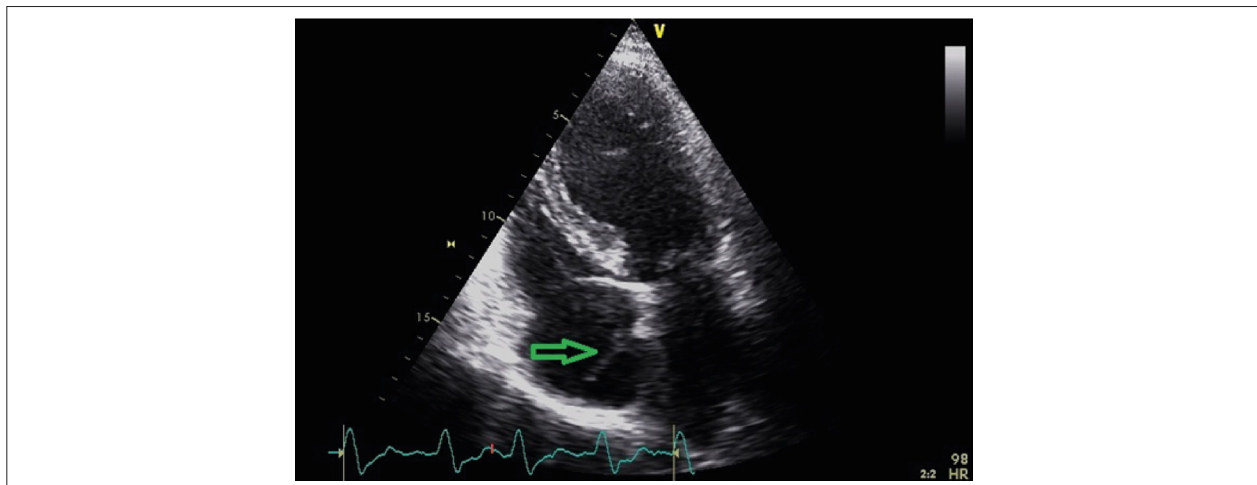


Figure 1 – Transthoracic apical 4-chamber view showing a right atrial mass with 30mm, apparently attached to interatrial septum.

Keywords

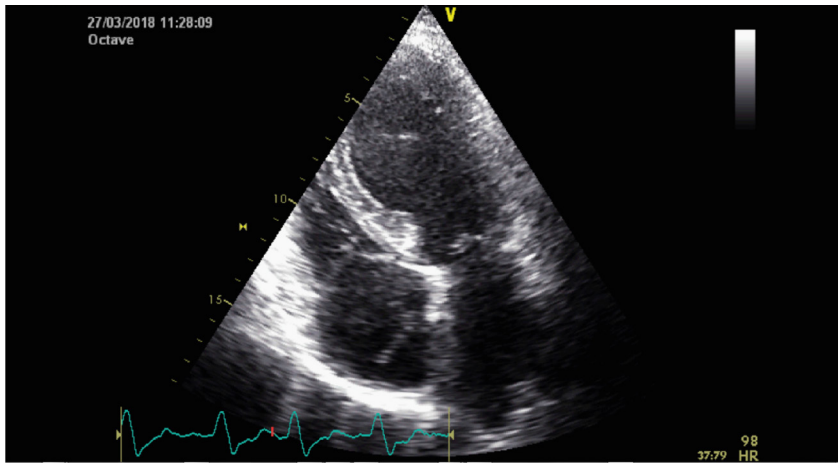
Cardiac resynchronization-therapy devices; Endocarditis; Heart valves.

Mailing Address: Maria Inês Fiuza Branco Pires •

Serviço de Cardiologia, Centro Hospitalar Tondela-Viseu, EPE – Avenida Rei D. Duarte – 3504-509 – Viseu – E-mail: inesfbpires@gmail.com
Manuscript received 10/23/2020; revised 11/9/2020; accepted 11/17/2020

DOI: 10.47593/2675-312X/20213401eabc161





Video 1 – Transthoracic apical 4-chamber view showing a right atrial mass with 30mm, apparently attached to interatrial septum.

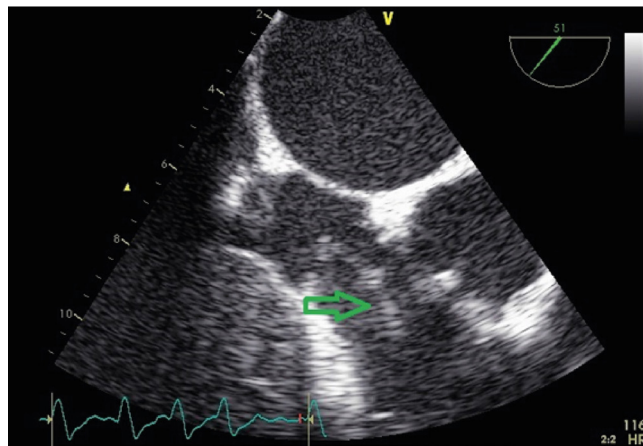
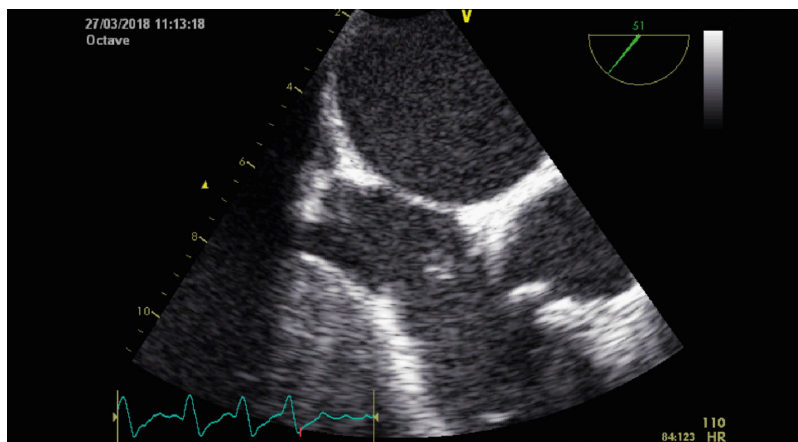


Figure 2 – Midesophageal modified bicaval view showing a mobile filamentous mass attached to the Eustachian valve.



Video 2 – Midesophageal modified bicaval view showing a mobile filamentous mass attached to the Eustachian valve.

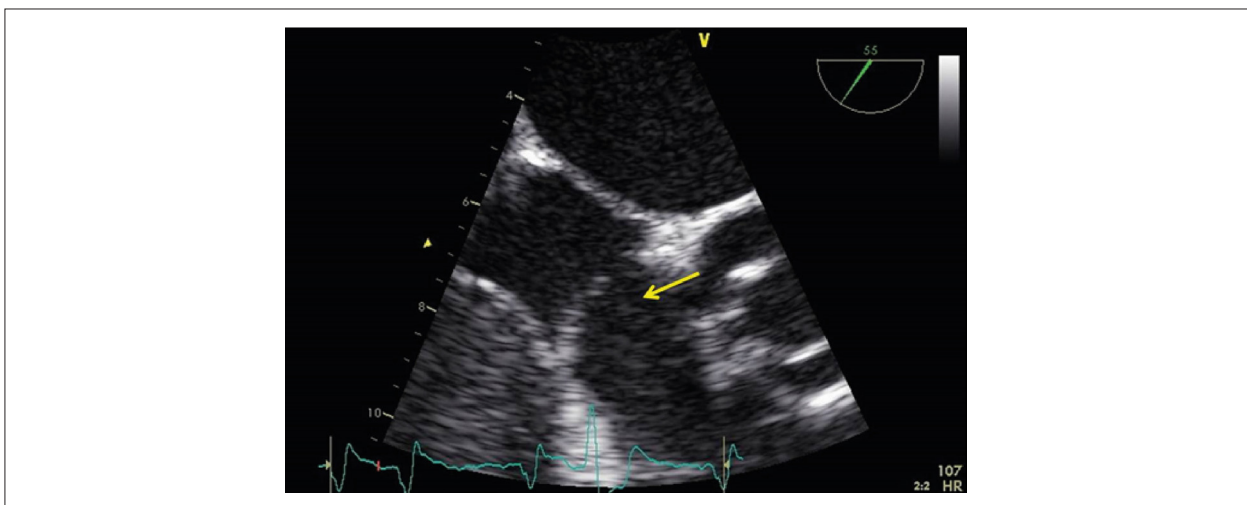
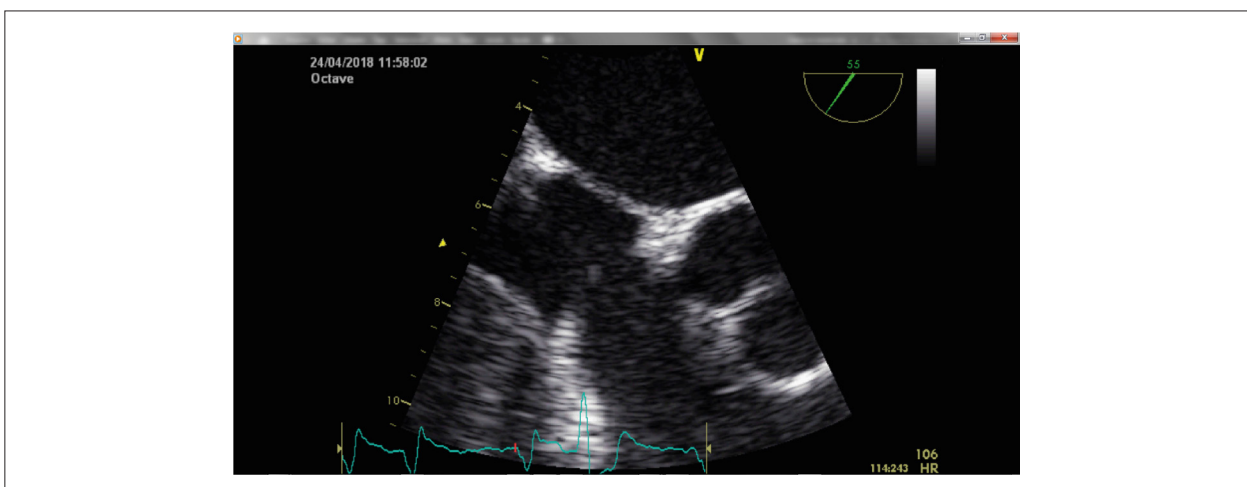


Figure 3 – Modified bicaval view revealing the decrement of vegetation size during antimicrobial therapy.



Video 3 – Modified bicaval view revealing the decrement of vegetation size during antimicrobial therapy.