

Cardiac Metastasis in Patient with Rectal Carcinoid Tumor

Metástase Cardíaca em Paciente com Tumor Carcinoide Retal

Iuri Shen de Lacerda¹, Priscilla Ornellas Neves², Lucianno Henrique Pereira Santos³, Joalbo Matos Andrade^{2,4}

Hospital Universitário de Brasília, Universidade de Brasília, DF¹, Santa Luzia Hospital - Rede D'Or São Luiz, DF², Grupo Acreditar, Rede D'Or São Luiz, DF³, LifeScan – Medicina Diagnóstica, Brazil.⁴

Introduction

Carcinoid tumors are neuroendocrine tumors derived from enterochromaffin cells which are widely distributed in the body. For this reason, they may be found at any location in the body, but they are traditionally described as originating from the foregut, midgut and hindgut. These are relatively uncommon, with an annual incidence of 2.4 to 4.4 per 100,000 people in the general population.¹ We report the case of a patient with rectal carcinoid tumor and metastatic involvement of the heart.

Case Report

A 51-year-old man with a history of rectal bleeding was referred to the proctologist and was submitted to rectosigmoidoscopy, which showed a rectal polyp. (Figure 1) Resection of the polyp was performed and carcinoid tumor was histopathologically diagnosed. These tumors form a heterogeneous group of neoplasms that are best worked up and managed with a variety of clinical and imaging techniques. With this diagnosis, the first objective was to stage the disease, so the patient was submitted to thoracic and abdominal computed tomography (CT). The main goal in this case presentation is to show an unusual form of cardiac involvement from a primary rectal neuroendocrine tumor and the use of multiple imaging studies to properly stage the disease and follow up the patient.

Thoracic and abdominal CT scan revealed several pelvic lymphadenomegaly sites adjacent to the rectosigmoid, a single hepatic lesion in the right lobe, measuring 7.6 cm and multiple metastatic cardiac lesions, all lesions characterized with central areas of low attenuation after intravenous contrast injection.

The staging of neoplastic disease is an important step in patients with recent tumor diagnosis, and, in this clinical scenario, with the detection of cardiac lesions, an unusual finding, other diagnostic imaging methods were necessary for a proper evaluation. With the results of thoracic and abdominal CT scan, the patient underwent single photon emission

computed tomography (SPECT) using octreotide, a radiotracer analogue to somatostatin, used as a marker of neuroendocrine tumors. Liver and heart lesions showed intense enhancement after the use of octreotide, leading to the diagnosis of multiple metastatic neuroendocrine tumor. (Figure 2)

Echocardiogram and cardiac magnetic resonance imaging were performed to better evaluate the cardiac lesions. The patient had no heart symptoms.

Transthoracic echocardiogram showed normal left ventricular function, tricuspid valve and subvalvular structures, with multiple heterogeneous solid cardiac tumors, the largest lesion centered in the inferior segment of the interventricular septum, with 7.0 cm in the long axis. (Figure 3) Echocardiography was performed mainly to check the existence of cardiac lesions and to rule out valvar involvement in this disease.

Cardiac magnetic resonance imaging (MRI) confirmed the distribution of cardiac solid tumors in all cardiac chambers, intensely enhanced after the injection of the contrast media. (Figure 4) Cardiac MRI is an important imaging method in this clinical situation, as it can confirm the presence of lesions on the echocardiogram and better define their number, dimension and location, and it is especially important in patient follow-up.

Discussion

Carcinoid tumors are rare and slow growing. They can be classified into tumors of the foregut (bronchus, stomach, proximal duodenum, pancreas), midgut (distal duodenum, jejunum, ileum, right colon) and hindgut (distal large bowel and rectum). They rarely occur in other organs such as ovaries, kidney and prostate.²

Rectal carcinoids are typically small, localized, nonfunctioning tumors that rarely metastasize. They comprise 12.6% of all carcinoid tumors and represent the third largest group of gastrointestinal carcinoids in Western countries. The frequency of rectal carcinoids is higher in studies from South Korea (48%) and Taiwan (25%) compared to Western countries.²

Diagnosis is based on tissue examination, usually of a biopsy from the primary tumor or liver metastasis. However, in some patients, attempts to collect histologic material can fail and, in these cases, diagnosis can be based on symptoms combined with radiologic and scintigraphic findings. Somatostatin receptors are located on the cell membranes of carcinoid tumors. Octreotide analogues have a high affinity with these receptors and sensitivity of this scintigraphy technique has been reported to range from 80% to 90%.³

Treatment of rectal carcinoids depends on tumor size.

Keywords

Magnetic Resonance Imaging; Tomography; Carcinoid Tumor; Heart; Neoplasm Metastasis.

Mailing Address: Iuri Shen de Lacerda •

SQSW 306, Bloco C, Apartamento 602. Postal Code 70673-433, Brasília, DF – Brazil.

E-mail: iurishen@outlook.com

Manuscript received 4/27/2019; revised 5/9/2019; accepted 8/23/2019

DOI: 10.5935/2318-8219.20190052

Case Report

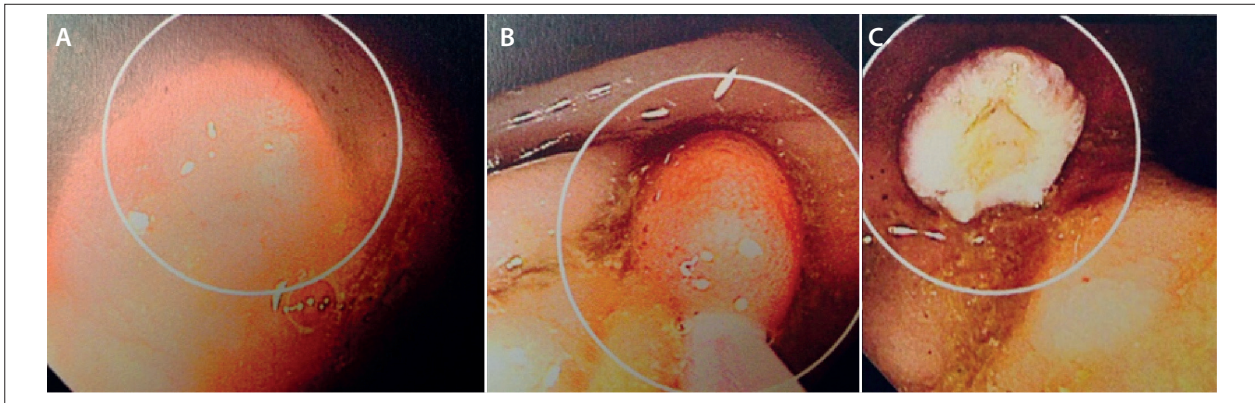


Figure 1 – Endoscopic views. A and B: Submucosal rectal lesion. C: Excised lesion.

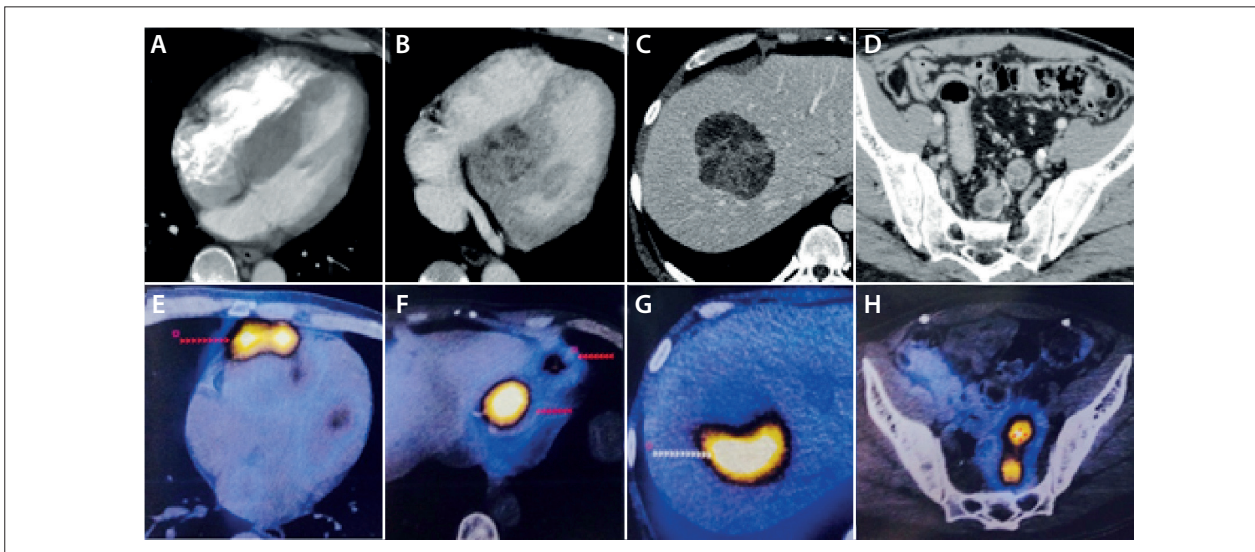


Figure 2 – Thoracic and abdominal CT (A-D) and SPECT-CT scan with octreotide (E-H). A and B: Multiple cardiac metastatic lesions. C: Isolated hepatic metastatic lesion. D: Pelvic lymphadenopathies adjacent to the rectum. E and F: Cardiac metastatic lesions with intense uptake of octreotide. G: Hepatic metastatic lesion with intense uptake of octreotide. H: Pelvic lymphadenopathies with intense uptake of octreotide.

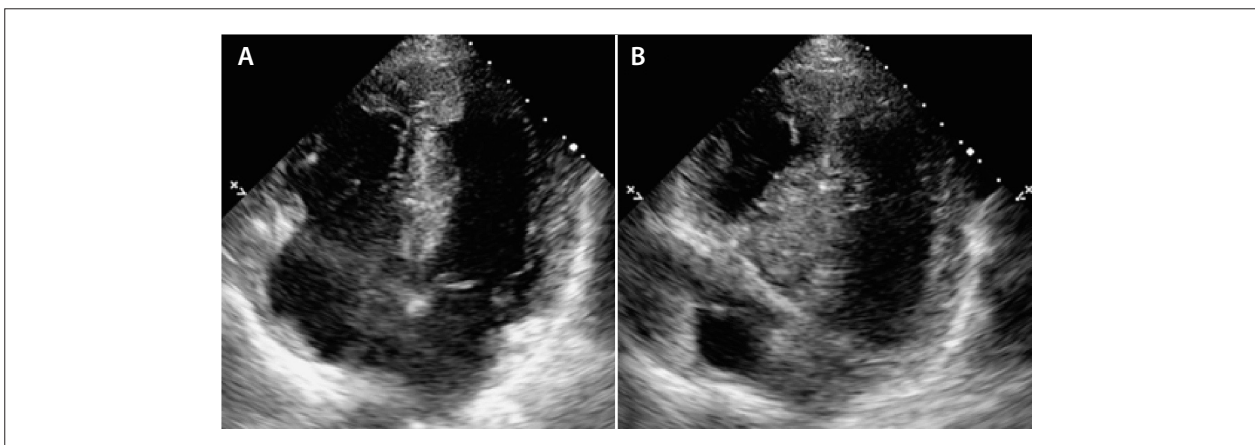


Figure 3 – Echocardiography images. A and B: Multiple echogenic cardiac metastatic lesions in the right ventricle wall and apical and septal left ventricle wall.

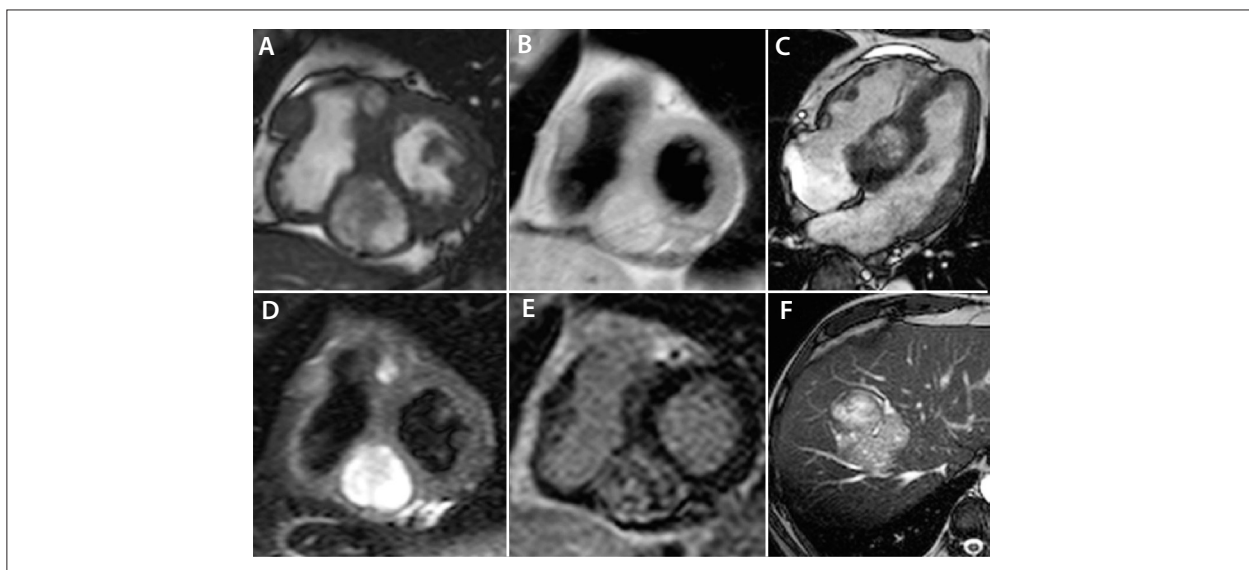


Figure 4—Magnetic resonance imaging. Multiple cardiac metastatic lesions (A-E). A and C: Cardiac short axis and four-chamber steady state images. B and D: Cardiac short-axis double and triple inversion-recovery images. E: Cardiac short-axis late enhancement image. F: Isolated hepatic metastatic lesion, abdominal axial steady state image.

Consensus guidelines on the management of rectal carcinoids suggest that small tumors (<1–2 cm) confined to mucosa or submucosa can be managed with endoscopic resection due to their low risk of metastatic spread.⁴ Our patient has been treated with somatostatin analogues and remained with stable hepatic and cardiac diseases.

Depending on their site of origin, carcinoid tumors can have the ability to secrete vasoactive peptides. Serotonin (5-hydroxytryptamine) production is the most prominent, especially in midgut tumors. Usually, only carcinoid tumors that invade the liver result in pathological changes to the heart. Cardiac disease is a late complication and occurs in 20%–70% of patients with metastatic carcinoid tumors. Cardiac manifestations are caused by the paraneoplastic effects of vasoactive substances released by malignant cells rather than any direct metastatic involvement of the heart. The characteristic pathological findings are endocardial plaques of fibrous tissue that may involve the tricuspid valve, pulmonary valve, cardiac chambers, venae cavae, pulmonary artery and coronary sinus. Once the carcinoid syndrome is established, approximately 50% of the patients develop carcinoid heart

disease. In many of them, the cause of death is attributed directly to cardiac disease.⁴

In our case, the patient presented no cardiac valvular involvement and no carcinoid syndrome since diagnosis. A literature review indicates that this is the first reported case in which carcinoid polyp was diagnosed simultaneously with metastatic involvement, and even more unusual is the presence of multiple solid metastatic cardiac tumors without valvular involvement and no carcinoid syndrome.

We can conclude that the use of multiple cardiac imaging techniques is important to better diagnose, stage and follow up a patient with an unusual neoplastic rectal disease with metastatic involvement of the heart.

Authors' contribution

Data acquisition: Lacerda IS, Andrade JM. Data analysis and interpretation: Lacerda IS, Andrade JM, Neves PM, Santos LHP. Manuscript writing: Lacerda IS, Andrade JM. Critical revision of the manuscript for important intellectual content: Lacerda IS, Andrade JM, Neves PM, Santos LHP.

References

1. Calero Rueda MJ, Aldamiz-Echevarría G, López AA, Almaraz CS, Romero AG, Sánchez-Aquino R, et al. Cardiac metastasis in a patient with a bronchial carcinoid. *Circulation*. 2014;130:e1–e3.
2. Datta S, Williams N, Suortamo S, Mahmood A, Oliver C, Hedley N, et al. Carcinoid syndrome from small bowel endocrine carcinoma in the absence of hepatic metastasis. *Age Ageing*. 2011;40(6):760–2.
3. Pellikka PA, Tajik AJ, Khandheria BK, Seward JB, Callahan JA, Pitot HC, et al. Carcinoid heart disease. Clinical and echocardiographic spectrum in 74 patients. *Circulation*. 1993;87(4):1188–96.
4. Anthony LB, Strosberg JR, Klimstra PDS, Maples WJ, Dorisio TMO, Warner RR, et al. North American Neuroendocrine Tumor Society (NANETS). The NANETS Consensus Guidelines for the Diagnosis and Management of Gastrointestinal neuroendocrine tumors (nets): well-differentiated nets of the distal colon and rectum. *Pancreas*. 2010;39(6):767–74.