Atypical Presentation of Ventricular Septal Defect Following Myocardial Infarction

Eduardo Cavalcanti Lapa Santos,[1,2] Sandro Gonçalves Lima,[1,2] Brivaldo Markman Filho,[1,2] Andréa Bezerra de Melo da Silveira Lordsleem,[1,2] George Augusto da Fonseca Carvalho Antunes Lima,[1,2] Priscila Costa dos Santos Moreira[1]

Hospital das Clínicas UFPE (HC-UFPE);[1] Universidade Federal de Pernambuco (UFPE),[2] Recife, Pernambuco – Brazil

Introduction

Ventricular septal defect (VSD) is a rare complication of myocardial infarction (MI). The decrease in the incidence of this complication (1 to 2% in the pre-thrombolytic age to about 0,2% currently) has been attributed to the earlier and more effective treatment of MI. Patients typically present with a sudden onset hemodynamic impairment accompanied by a new heart murmur. Despite the advances of surgical assistance, mortality remains high (25 - 87%). We report an atypical case of VSD following MI where the patient was olygosymptomatic and had the diagnosis weeks after the acute event.

Case Report

A 73-year-old male patient was admitted in the emergency department due to typical chest pain lasting approximately 30 minutes. He reported a history of systemic arterial hypertension. He was discharged from the hospital hours later without a confirmed diagnosis. Over the following weeks, he persisted with chest pain on moderade exertion, associated with dyspnea. Two months later, the patient was evaluated in an outpatient service where a regurgitative holosystolic murmur was heard on the left lower sternal border (3+/6+). The resting electrocardiogram showed left ventricular hypertrophy and negative and symmetrical T waves in lower leads. He was referred to our service where an echocardiogram revealed VSD in the basal portion of the inferior septal wall (Video 1) and an aneurysm in basal portion of the inferior wall.

Cardiac catheterization showed 3-vessel disease with an occluded right coronary artery (RCA). Ventriculography confirmed the VSD as well as the aneurysm of the basal portion of the lower wall (Video 2).

The patient was submitted to surgical correction of the VSD and resection of the aneurysm (Figure 1). Mammary bridge sequential to the diagonal branch and to the left anterior descendent artery was also performed. The patient had no postoperative complications.

Keywords

Myocardial Infarction; Thoracic Surgery; Heart Septal Defects, Ventricular; Echocardiography.

Mailing Address: Eduardo Cavalcanti Lapa Santos •
Hospital Dom Helder Câmara – HDH
BR 101 Sul Km 28m Cabo de Santo Agostinho. Postal Code 54510-000, Pernambuco, Recife – Brazil
E-mail: eduardolapa@gmail.com
Manuscript received July 25, 2017; revised August 17, 2017; accepted August 17, 2017

DOI: 10.5935/2318-8219.20170029

Discussion

Ventricular septal defect (VSD) is a rare complication of myocardial infarction (MI).[1,2] The reduced incidence of this complication (1 to 2% in the pre-thrombolytic age to about 0,2% currently) has been attributed to the earlier and more efficient management of MI.[3-5] The cases classically present with an abrupt onset of hemodynamic impairment accompanied by a new heart murmur.[6] Despite the advances of surgical assistance, mortality remains high (25 - 87%).[7]

Patients often have total coronary occlusion responsible for the ischemic event, suggesting that the mechanism involves a sudden and severe ischemic event, leading to extensive tissue necrosis.[4] Reperfusion, especially if initiated early, is able to prevent myocardial necrosis that is typically associated with septal complications (40%).[3]

Factors associated with a higher risk of developing rupture of the interventricular septum after an acute ischemic event are listed in Table 1.[4,8]

The clinical presentation is usually marked by manifestations of hemodynamic instability:[9] cardiogenic shock, refractory pulmonary edema and the need for vasoactive drugs.[9] In 90% of the cases, a new cardiac murmur can be detected.[6]

Several complementary methods can be used to diagnose VSD following MI: echocardiogram, cardiac catheterization, pulmonary artery catheterization, cardiography.[1,4] The most commonly used method is echocardiography.[6]

The clinical management of post-myocardial infarction VSD includes medications and support devices such as intra-aortic balloon and are intended to reduce afterload and consequently reduce left-right shunt until surgical and/or definitive intervention.[5,9] But it is noteworthy that VSD patients with in GUSTO-I selected for surgical repair had better results than those treated medically.[4] On the other hand, those who advise against an early approach recommend to wait for the patient to recover and for the completion of the cicatricial process around the VSD.[3] The timing of repair of VSD after MI is still debatable.[3]

Currently, the percutaneous approach may be offered as a less invasive option for the immediate and long-term closure of the VSD.[3] Even with the advances of the surgical approach, interventricular septal repair in these cases remains a challenging surgical procedure associated with high early mortality.[5]

Conclusion

Ventricular septal defect is a serious complication after MI, usually presenting with hemodynamic instability. We report

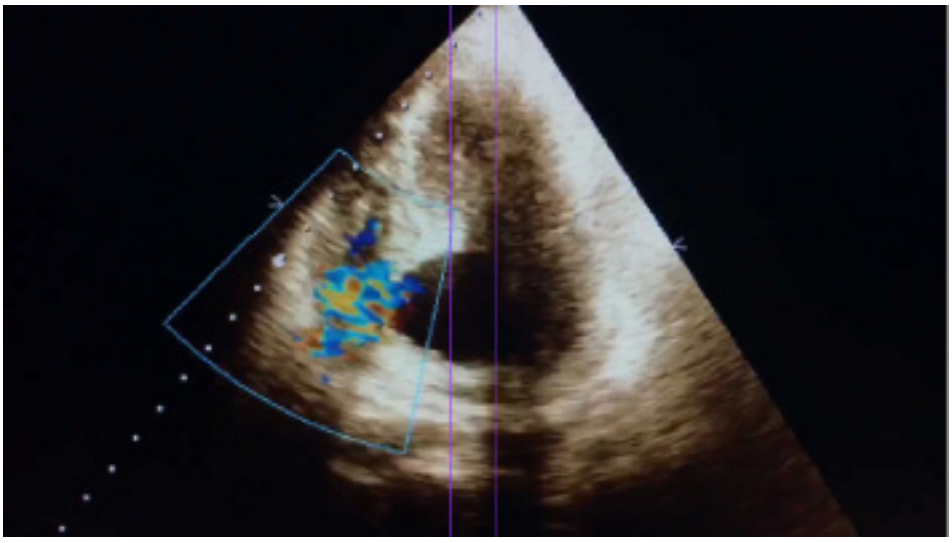

Video 1 – *Echocardiographic image revealing VSD in the basal portion of the inferior-septal wall. Watch the videos here: http://departamentos.cardiol.br/dic/publicacoes/revistadic/2017/v30_4/video_v30_4_191_ingles.asp*

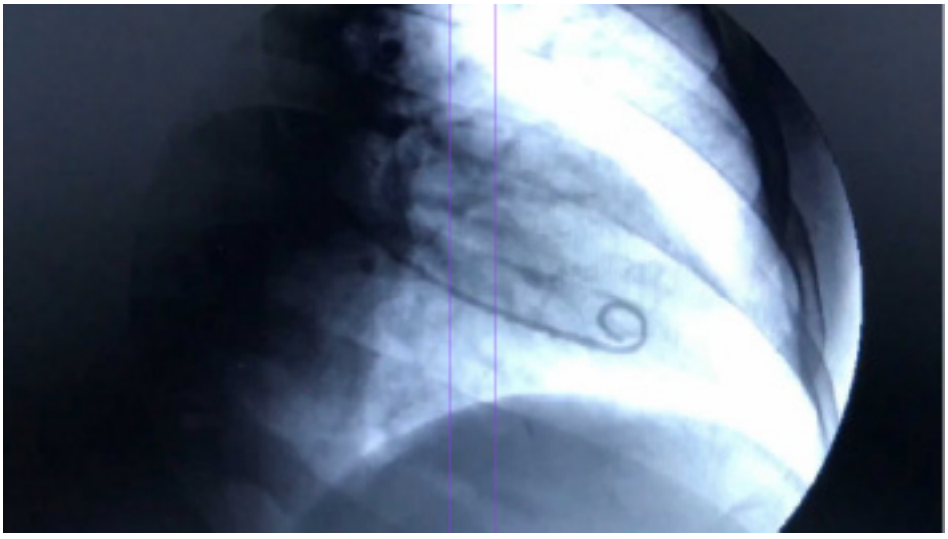

Video 2 – *Ventriculography image confirmed the VSD as well as the aneurysm of the basal portion of the inferior wall. Watch the videos here: http://departamentos.cardiol.br/dic/publicacoes/revistadic/2017/v30_4/video_v30_4_191_ingles.asp*

the atypical case of a patient who had a diagnosis of post-MI months after the initial acute coronary event.

Authors' contribution

Research creation and design: Santos ECL; Data acquisition: Moreira PCS; Data analysis and interpretation: Markman Filho B; Manuscript drafting: Lima GAFCA; Critical review of the manuscript as for important intellectual content: Santos ECL, Lima SG, Lordsleem ABMS; Translation: Santos ECL, Lima GAFCA, Moreira PCS.

Potential Conflicts of Interests

There are no relevant conflicts of interests.

Sources of Funding

This study had not external funding sources.

Academic Association

This study is not associated with any graduate programs.

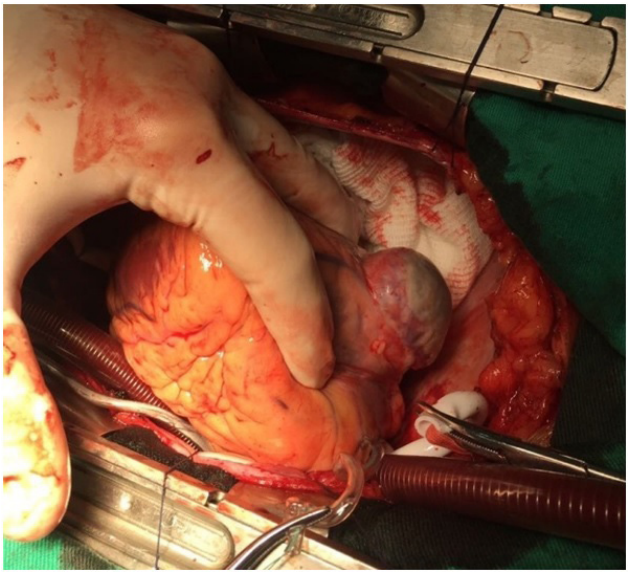

Figure 1 – *Photograph of the aneurysm during VSD surgical correction with resection of the aneurysm.*

Table 1 – Factors associated with the development of post-acute myocardial infarction VSD[4,8]

Women	Advanced age
No history of smoking	Anterior wall infarction
Tachycardia at baseline	Systemic arterial hypertension
Worst class Killip on admission	Flow TIMI I and II in the culprit artery

References

1. Iyer, S, Bauer, T, Yeung, M, Ramom C, Kiser AC, Caranasos TG, et al. A heart team and multi-modality imaging approach to percutaneous closure of a post-myocardial infarction ventricular septal defect. *Cardiovasc Diagn Ther*.2016;6(2), 180–4.Doi: 10.21037/cdt.2015.10.04

2. Jin, S, Kim, M, Lee J, Choi S-W, Man JH, Jin S-A, et al. Successful device closure of a post-infarction ventricular septal defect. *Clin Interv Aging*. 2016;*11*, 927–31. Doi: 10.2147/CIA.S107470.

3. Sabiniewicz R, Huczek Z, Zbroński K, Scislo P, Rymuza B, Kochman J, et al. Percutaneous closure of post-infarction ventricular septal defects–an over decade-long experience. *J Invasive Cardiol*. 2017; *30*(1): 63–71. Doi:10.1111/joic.12367.

4. Crenshaw BS, Granger CB, Birnbaum Y, Pieper KS, Morris DC, Kleiman NS, et al. Risk factors, angiographic patterns, and outcomes in patients with ventricular septal defect complicating acute myocardial infarction. GUSTO-I (Global Utilization of Streptokinase and TPA for Occluded Coronary Arteries) Trial Investigators. *Circulation*. 2000;101(1):27-32. PMID: 10618300.

5. Singh V, Rodriguez AP, Bhatt P, Alfonso CE, Skhuja R, Palacios IF, et al. Ventricular septal defect complicating elevation myocardial infarctions: a call for action. *Am J Med*.2017;130(7):863.e1-863.e12. Doi: 10.1016/j.amjmed.2016.12.004.

6. Pinto FPC, Silva HC, Gonçalves RMGM, Bartholo TP. CIV pós-IAM de parede inferior com ótima evolução pós-operatória: apresentação incomum de uma complicação cada vez menos freqüente. Rev SOCERJ.2006;19(6):539-41.

7. Mangovski, L, Kozlik-Feldmann R, Peric, M, Jovovic L, Farkie M, Dekic D. Challenges in treatment of postinfarction ventricular septal defect and heart failure. *Vojnosanit Pregl*. 2015;*72*(1), 68–71. PMID:26043595

8. Rodrigues A S, Pena M I, Crepaldi R J, Vasconcelos JVS, Miranda RA, Pereira LFC. Pseudoaneurisma e CIV pós-IAM concomitantes: apresentação grave e rara. *Rev Bras Cardiol*. 2013;*26*(3), 209–12.

9. Daggett W M, Guyton R A, Mundth E D, Buckley MJ, McEnany MT, Gold HK, et al. Surgery for post-myocardial infarct ventricular septal defect. *Ann Surg*. 1977;*186*(3), 260–71. PMCID:PMC 1396347